

# Differences in Hymenal Morphology Between Adolescent Girls With and Without a History of Consensual Sexual Intercourse

Joyce A. Adams, MD; Ann S. Botash, MD; Nancy Kellogg, MD

**Objective:** To compare the morphology of the hymen in adolescent girls who have and have not had sexual intercourse involving penile-vaginal penetration.

**Subjects:** Female patients aged 13 to 19 years, recruited from an urban adolescent medicine practice.

**Methods:** Subjects were interviewed in private after completing detailed questionnaires and then underwent a physical examination. External genital inspections were performed using a colposcope with an attached 35-mm camera to document the appearance of the hymen. The presence of notches or clefts was recorded during the examination, and photographs taken at  $\times 10$  magnification were used to take measurements of the width of the posterior hymenal rim.

**Results:** Posterior hymenal notches and clefts were more common among girls admitting past intercourse (13/27 [48%]) than in girls who denied intercourse (2/58 [3%];  $P = .001$ ), but the mean width of the posterior hymenal rim was not significantly different between the 2 groups (2.5 mm vs 3.0 mm;  $P = .11$ ). Two subjects who denied intercourse but had posterior hymenal clefts described a painful first experience with tampon insertion.

**Conclusions:** Deep notches or complete clefts in the posterior rim of the hymen were rare in girls who denied intercourse. Subjects who admitted past intercourse still had nondisrupted, intact hymens in 52% of cases.

*Arch Pediatr Adolesc Med.* 2004;158:280-285

THE AMERICAN ACADEMY OF Pediatrics, Elk Grove, Ill, recommended in 1989 that all adolescent girls have an external genital examination as part of their physical examination to look for abnormalities of the hymen and other genital tissues.<sup>1</sup> In practice, however, asymptomatic adolescent girls may not undergo a genital examination unless there is suspicion of sexual abuse or previous consensual sexual activity. The physician performing the examination is then expected to determine whether there has been vaginal penetration. There is a paucity of data available to assist in that determination.<sup>2</sup>

While there have been studies to obtain normative data on the appearance of the hymen and other genital tissues in newborn infants and prepubertal girls selected for nonabuse,<sup>3-5</sup> the only published study comparing adolescent girls who were consensually sexually active with those who were not<sup>6</sup> did not use magnification, such as a colposcope, and did not use photographs to document the appearance of the hymen. The lack of photo-

graphs precludes peer review by blinded experts. In many centers where children and adolescents are evaluated for possible sexual abuse, photographs are taken with a camera attached to a colposcope to document any abnormal findings.<sup>7</sup> Detailed, magnified, and objective photodocumentation is therefore necessary to adequately compare the appearance of the hymen in girls who have never experienced vaginal penetration (abuse or consensual) with those who admit having had vaginal intercourse.

In a case-control study<sup>8</sup> of prepubertal girls aged 3 to 8 years, only girls who described digital-vaginal or penile-vaginal penetration were found to have deep notches or complete clefts in the posterior rim of the hymen or measurements of the posterior rim of the hymen at the midline less than 1 mm wide. A deep notch was defined as a V-shaped defect extending through more than 50% of the width of the hymen. A complete cleft was defined as a defect that extended through the entire rim of hymen, all the way to the fossa or vestibular wall.

The purpose of this study was to determine the frequency of anterior, lat-

From the University of California, San Diego (Dr Adams); Upstate Medical University, Syracuse, NY (Dr Botash); and the University of Texas Health Science Center, San Antonio (Dr Kellogg).

eral, and posterior notches and complete clefts in the hymen in adolescent girls who had never had vaginal intercourse and to compare the frequency of hymenal notches and clefts and mean width of the hymen at the midline between subjects who admitted and those who denied having experienced penile-vaginal intercourse.

## METHODS

The study was approved by the Human Subjects Committee of the University of California, San Diego. Female patients aged 13 to 19 years were recruited from a university adolescent medicine practice at 2 locations in San Diego between June 1, 1997, and December 1, 2000. Inclusion criteria were age, having begun menstruation, and having a parent present to sign a consent form if the patient was younger than 18 years. A history of past pregnancy or abortion, past episodes of forced sexual intercourse, and diagnoses of anorexia nervosa or anxiety disorder were exclusion criteria.

Written informed consent was obtained, and both patients and parents were informed that the interview would include screening questions for emotional and behavioral problems and that the entire visit would be provided free of charge. Patients were informed that they would receive \$50 for participation in the study.

The parent was asked to complete a questionnaire concerning the patient's health, health history, and any behavioral or emotional concerns. At the same time, the patient completed a questionnaire adapted from a previous study,<sup>9</sup> which included questions concerning home, education, activities, past physical or sexual abuse, drug use, depression, suicide ideation or attempts, and past experience with penile-vaginal intercourse.

A complete physical examination including a detailed examination of the external genitalia using a colposcope was done in an office setting with the mother or other support person present if the patient so desired. All examinations were conducted by 1 of us (J. A. A.). Patients were placed on the examination table in the lithotomy position, and the external genitalia were carefully examined using separation of the labia majora and minora and labial traction, with the patient watching the examination on the video monitor if she chose to do so.

Using a cotton applicator swab moistened with water, the edge of the hymen was gently stretched to clearly define the amount of tissue present at the 6-o'clock position of the posterior rim. In addition, any areas that appeared to be notches or clefts in the hymen were spread apart with the swab as well to define the depth of the notch or cleft. A larger cotton swab with the tip covered by a latex balloon was used in some patients to help visualize the notches or clefts in the hymen.

Photographs were taken using a 35-mm camera (Nikon, Melville, NY) attached to a colposcope (Cryomedics MM6000; Cabot, Cryomedics Inc, Langhorne, Pa) at  $\times 6$  or  $\times 10$  magnification. A photo log sheet was kept to match the subject number to the imprinted numbers on the slides, and notations were made of the location of notches or clefts identified during the examination.

All colposcopic slides were reviewed by 1 of us (J. A. A.) in order to record details of hymenal appearance, including verification of the location of notches or clefts noted during the examination. Measurements of the width of the hymenal rim at the 6-o'clock position were taken using a calibrated measuring device. All slides were projected onto the screen using a slide projector (Kodak Ektagraphic, Rochester, NY). Slides of a millimeter ruler taken at  $\times 6$  and  $\times 10$  magnification were each projected in the same way, and a cardboard ruler was made to match the projected image of each ruler. These rulers were then

used to take the hymen measurements from the projected images for each subject. The width of the posterior hymenal rim was measured from the projected slides at the 6-o'clock position, between the edge of the hymen and the base of the hymen where it meets the vestibular fossa inferiorly.

Slides from all subjects whose photographs clearly showed the entire hymenal rim were sent to 2 additional experts in adolescent gynecology (A. S. B. and N.K.). Both reviewers were experienced in reviewing colposcopic photographs; each had examined more than 1000 children and adolescents for suspected sexual abuse. The reviewers were blinded to the patients' sexual histories and were asked to describe the location of any deep notches or complete clefts in the hymen, using the definitions of Berenson et al<sup>8</sup> described previously.

The data were entered into a computer database, along with the answers given by the patient and parent on the questionnaires. The Student *t* test was used to compare continuous variables between subjects who said they had engaged in intercourse involving penile-vaginal penetration (admitted) and those who said they had never experienced (denied) such contact. A  $\chi^2$  analysis was done for grouping variables. SPSS software (SPSS Inc, Chicago, Ill) was used for all analyses, and *P* values  $< .05$  were considered significant.

## RESULTS

A total of 85 subjects were recruited, with a mean age of 16.5 years. A log was not kept of the number of patients who were approached about participating but declined. It is estimated that only 1 patient in 10 agreed to participate in the study.

There were 58 subjects who denied ever experiencing penile-vaginal intercourse and 27 subjects who admitted consensual sexual activity involving penile-vaginal intercourse. The mean age of the subjects who reported having had intercourse was significantly higher than that of the subjects who denied sexual intercourse (17 years vs 15.5 years;  $P = .001$ ). Of the 58 subjects who denied sexual intercourse, 52 used tampons and 6 did not. Of the subjects using tampons, 25 (48%) reported experiencing both pain and difficulty with insertion of the tampon on first attempt at using them.

### OUTSIDE REVIEW OF SLIDES

Initial difficulties with equipment resulted in poor-quality photographs being available for 18 subjects. Slides of the remaining 67 subjects (45 with no history of past intercourse and 22 with a history of consensual intercourse) were sent to the 2 reviewers, as previously described. The reviewers were blinded to the subjects' sexual histories.

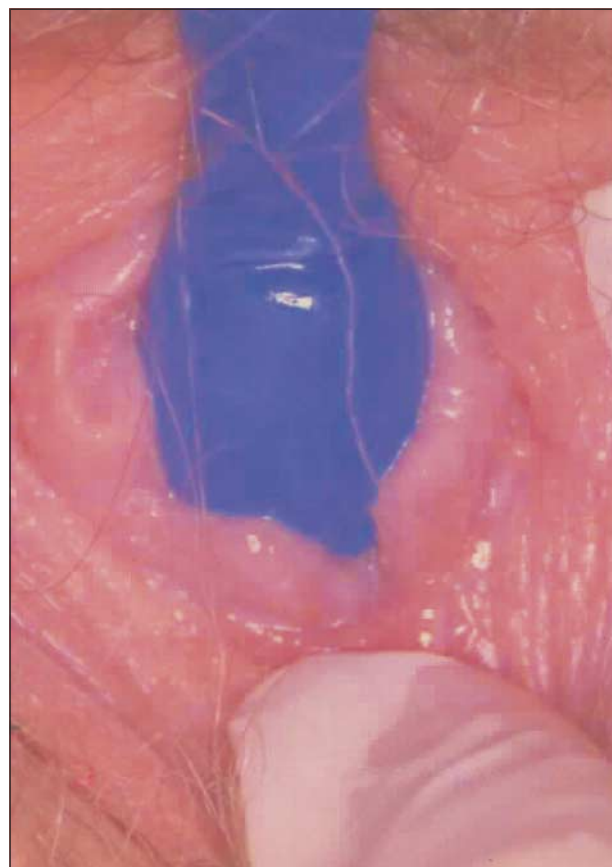Both reviewers agreed with the examiner on the absence of deep notches or complete clefts in the hymens of 37 (82%) of 45 subjects. Both also agreed on the presence of deep notches or clefts in 18 (90%) of 20 subjects. For 2 of the subjects, neither reviewer could determine from the photographs whether notches or clefts were present. Using the Cohen  $\kappa$  statistic,<sup>10</sup> agreement between the examiner and each reviewer for the absence or presence of any notches, notches at the lateral location, and notches at the posterior location ranged from  $\kappa$  values of 0.71 to 0.85, all with  $P < .001$ .

**Table 1. Comparison of Notches and Clefts in the Hymen in Subjects With and Without a History of Sexual Intercourse\***

	No History of Intercourse (n = 58)	History of Intercourse (n = 27)	P Value
Anterior†			
Deep notch‡	1 (2)	2 (7)	.37
Lateral†			
Deep notch‡	3 (5)	7 (26)	<.01
Complete cleft‡	3 (5)	7 (26)	<.01
Posterior†			
Deep notch‡	1 (2)	2 (7)	.54
Complete cleft‡	1 (2)	9 (33)	<.001
Deep notch or complete cleft at lateral or posterior location or both	8 (14)	13 (48)	<.01

\*Using  $\chi^2$  analysis. Values expressed as number (percentage) of subjects.  
 †Anterior, located at the 2-o'clock or 10-o'clock position; lateral, located at the 3-o'clock or 9-o'clock position; posterior, located at the 8-o'clock through 4-o'clock position.

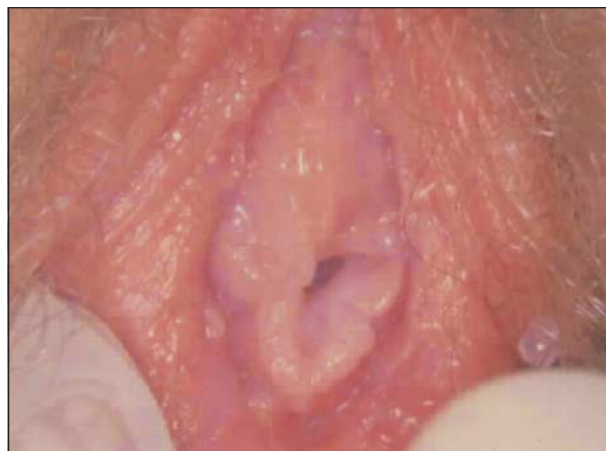‡Deep notch refers to a defect extending through more than 50% of the width of the hymen; complete cleft, a defect extending all the way through the width of the hymen.



**Figure 2.** The same subject as in Figure 1. A large cotton swab covered with a small latex balloon was used for contrast. A complete cleft in the hymen at the 5-o'clock position is clearly demonstrated.

### COMPARISON OF HYMENAL FINDINGS

Because the examiner was able to manipulate the hymenal tissue during the examination and make nota-



**Figure 1.** Photograph at  $\times 10$  magnification, showing a 19-year-old subject who admits to having consensual intercourse. Any notches or clefts in the hymen are unable to be clearly seen in this view.

tions concerning the presence of notches or clefts and their depth, these data, along with the measurements of the posterior hymenal rim taken from the colposcopic photographs, were used in the subsequent analysis. There were 4 subjects in the non-sexually active group who had a hymenal septum.

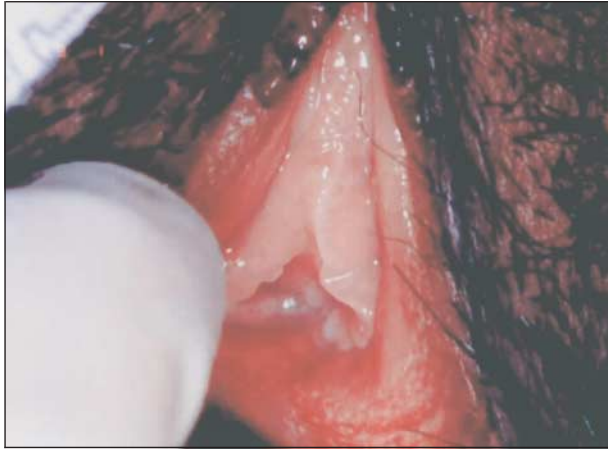The mean width of the hymenal rim was 2.5 mm among the subjects admitting past intercourse and 3.0 mm among the group who denied past intercourse. This difference was not statistically significant, using the *t* test for comparisons of means. Using the  $\chi^2$  test, however, there were significantly more subjects in the group admitting sexual intercourse than in the group denying intercourse with a posterior hymenal rim measurement of less than or equal to 1 mm wide (6/27 [22%] vs 3/58 [3%], respectively;  $P < .01$ ).

**Table 1** presents the frequency of deep notches and complete clefts in the anterior, lateral, and posterior locations, comparing subjects without a history of sexual intercourse and those with a history of past penile-vaginal intercourse. There were 14 (52%) of 27 subjects in the sexually active group who had no deep notches or complete clefts in either the lateral or posterior locations.

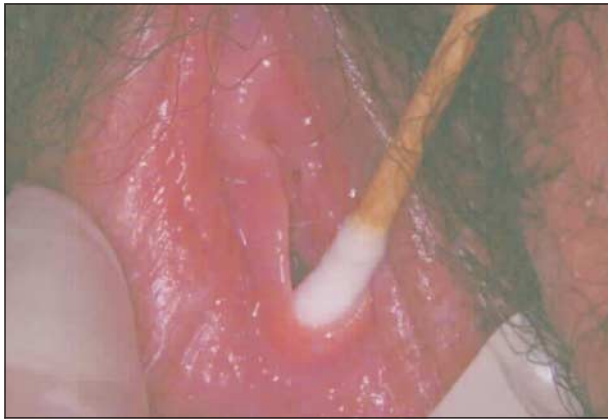**Figures 1, 2, 3, 4, and 5** demonstrate the use of swabs to stretch out the hymenal rim and provide documentation of the presence or absence of notches or clefts.

Two subjects who stated that they had never had sexual intercourse but had a posterior deep notch (subject 51) or complete cleft (subject 45) had described a painful insertion of a tampon in their first and only attempt to use them. Subject 45 described using a large tampon from her mother's supply, even though her own menstrual flow was very light at the time (Figure 3). Both of the outside reviewers of the photographs identified a deep notch or complete cleft in each of these 2 subjects.

Among subjects who denied intercourse, 5 (9%) had 1 notch or cleft in the posterior or lateral locations, and 5 (9%) had 2 notches or clefts. For the group admitting to past intercourse, 4 (15%) subjects had 1 notch or cleft, 6 (22%) had 2 notches or clefts, and 3 (11%) had 3 or



**Figure 3.** A 19-year-old subject with no history of past sexual intercourse (subject 45). She described the painful insertion of a tampon on 1 occasion. A complete cleft was seen in the hymen at the 6-o'clock position during the examination, but it was not as clearly documented in the photograph, taken at  $\times 10$  magnification.

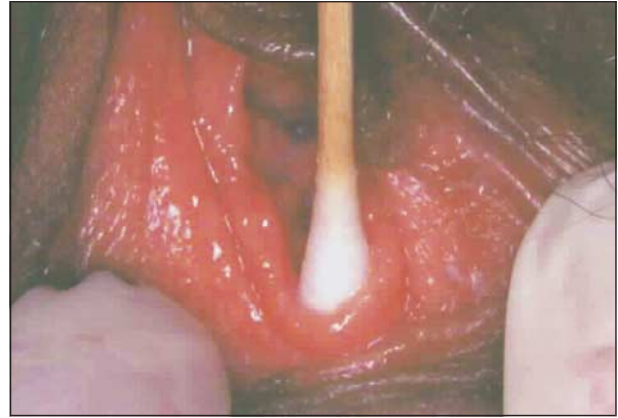


**Figure 4.** A 16-year-old sexually active subject who admits to consensual sexual intercourse. No notches or clefts were visible in the hymen during examination. The subject was able to relax and allow stretching of the hymenal rim with a cotton swab. The photograph was taken at  $\times 10$  magnification.

more. **Table 2** presents a comparison of the number of subjects with 0 to 1 and 2 to 4 notches or clefts in the posterior or lateral locations and between subjects with and without a history of sexual intercourse, using the Fisher exact test.

Since subject age was associated both with a higher likelihood of being sexually active and with a higher mean number of notches or clefts using the *t* test, a separate  $\chi^2$  analysis was done on the 58 subjects with no history of intercourse. There was no significant difference in the percentage of subjects with notches between the 3 age groups, 13- to 14-year-old (5/21 [24%]), 15- to 17-year-old (2/26 [8%]), and 18- to 19-year-old subjects (2/10 [20%]).

Lateral deep notches or complete clefts were found in 1 (10%) of 10 of the 18- to 19-year-old subjects with no history of intercourse and in 7 (63%) of 11 subjects in the same age group with a history of sexual intercourse ( $\chi^2$ ;  $P = .01$ ). Posterior deep notches or complete clefts were found in 2 (20%) of 10 of the older subjects with no history of intercourse, com-



**Figure 5.** A 15-year-old subject with no history of past sexual intercourse who did not use tampons. The subject was able to relax, and a cotton swab stretching out the rim of the hymen shows no notches or clefts. Note the similar appearance to the hymen shown in Figure 4.

**Table 2. Comparison of Number of Subjects With 0 to 1 and 2 to 4 Notches or Clefts in the Hymen\***

	0 to 1	2 to 4	Total
No history of intercourse	53 (91)	5 (9)	58
History of intercourse	18 (67)	9 (33)	27
<b>Total</b>			<b>85</b>

\*Using the Fisher exact test ( $P = .009$ ). Values expressed as number (percentage) of subjects.

pared with 7 (63%) of 11 older subjects with a history of past intercourse ( $\chi^2$ ;  $P = .046$ ).

To determine whether the number of posterior deep notches or complete clefts increased with the number of years a subject was sexually active, we calculated the number of years since the onset of sexual activity and compared this with the number of posterior or lateral hymenal defects in the 27 sexually active subjects. There was no significant correlation between years since sexual debut and the percentage of subjects with 0, 1 to 2, or 3 or more notches or clefts in the hymen, using  $\chi^2$  analysis.

#### COMMENT

To our knowledge, this study is the first to use magnification with a colposcope and photographs to document the appearance of the hymen in adolescent girls with and without a history of sexual intercourse. It is interesting to compare our results with those of Emans et al.<sup>6</sup> In their study, which did not use magnification, 6 (3%) of the 200 girls who denied past intercourse had complete clefts in the posterior rim of the hymen. This is the same frequency we found, and both of the girls with this finding in our study had described painful tampon insertion.

In the Emans study, 81% of the sexually active subjects were found to have complete clefts of the hymen during a nonmagnified examination, which is higher than the 48% frequency in our group of 27 subjects. The mean age of subjects in our study was 16 years

### What This Study Adds

The study by Emans et al<sup>6</sup> used nonmagnified examinations by 2 individual examiners to describe the appearance of the hymen in adolescent girls without a history of sexual intercourse, so an assessment of findings by a blinded reviewer was not possible. Although 3% of the subjects who denied intercourse had complete clefts in the posterior rim of the hymen, these were not attributed to the use of tampons.

In our study, photographs of 67 subjects were sent to 2 outside reviewers who were blinded to the subjects' history of intercourse, and both reviewers identified a deep notch in 2 (3%) of 58 subjects who denied intercourse but described painful past use of a tampon. We also found a lower frequency of hymenal clefts in a younger population of subjects who admitted sexual intercourse (48%) than was found by Emans et al in an older population (81%).

compared with 18 years in the Emans study, which could account for the difference in the percentage of subjects with deep notches or complete clefts in the lower portion of the hymen. When considering only 18- and 19-year-old subjects who admitted having had past intercourse, we did find that 63% had posterior hymenal defects (deep notches or complete clefts), compared with 48% in sexually active girls in the larger group of 27 subjects.

There are several limitations to our study, the most obvious being the reliance on the subjects to say whether they had experienced sexual intercourse involving penile-vaginal penetration. It is possible that the 2 subjects who said they had not had sexual intercourse but had posterior hymenal defects had, in fact, experienced sexual intercourse but denied it to the examiner. The responses of these 2 subjects to the other questions regarding family relationships; school functioning; use of alcohol, drugs, or tobacco; and past physical and sexual abuse or suicide attempt were similar to the responses of the other non-sexually active subjects, which suggests that they were indeed being truthful about not having experienced intercourse. However, there is no gold standard for determining virginity, and the subjects' disclosure of their status remains a less than perfect method.

The examiner in this study was not blinded to the subjects' histories of sexual intercourse, and this fact could be considered a limitation of the study. However, the high rate of agreement between the examiner and the blinded reviewers on photographs of 67 subjects added validity to the assessment of deep notches and clefts in the hymen.

Another limitation was the use of still photographs rather than videotapes of the colposcopic examinations to document the presence of notches or clefts in the hymen, because difficulties with the equipment limited the number of photographs that could be sent for outside review. In addition, the method of stretching out the hymenal edge with a cotton swab was not always successful, and on some photographs, the swab ob-

scured the defect the examiner was trying to demonstrate. Videotaped examinations and the use of the Foley catheter<sup>11</sup> to expose the hymenal rim may have allowed for a more comprehensive review of the findings by outside experts.

It would have been desirable to have a larger group of subjects who had neither used tampons nor engaged in penile-vaginal intercourse in order to study the isolated effects of tampon use on the appearance of the hymen. Girls who were not comfortable with tampon use were also likely to be uncomfortable with having an external genital examination using videocolposcopy and so were more difficult to recruit. However, it is reassuring that 50 of the 52 tampon users who denied intercourse were found to have a hymen without deep notches or clefts.

### CONCLUSIONS

Deep notches and complete clefts in the hymen at the 3-o'clock or 9-o'clock position, as well as in the posterior portion of the hymen, were found significantly more often in girls who admitted sexual intercourse compared with girls who denied having had sexual intercourse. Lateral or posterior deep notches or complete clefts in the hymen in adolescent girls should therefore be considered strongly suggestive of previous penetration. Whether the notches or clefts could have been caused by difficulty with tampon use or by speculum examinations must be assessed on a case-by-case basis.

Adolescent girls who have no deep notches in the hymen could still have experienced penile-vaginal penetration, because 52% of the subjects in this study who admitted past intercourse did not have deep notches or complete clefts in the lateral or posterior locations of the hymen. The absence of notches does not rule out previous penile-vaginal penetration in an adolescent. For this reason, the term *intact* should be avoided when describing a hymen that is free of clefts.

Further research is needed with a larger sample of girls who have had previous sexual intercourse to determine the factors that contribute to the presence, location, and number of notches and clefts in the hymen. Particularly useful would be longitudinal studies of adolescent girls through puberty, early adolescence, and into their young adult years to document the progressive changes in the hymen that may occur with tampon use or the onset of sexual activity. Additional longitudinal studies involving adolescents who have not had sexual intercourse are also needed.

Physicians, nurse practitioners, physician assistants, and nurses who examine and treat adolescent girls who have described being sexually abused continue to rely on the patient's description of the alleged assault. The absence of any injury to the hymen should not be used as a reason to negate the possibility that the adolescent has experienced vaginal penetration.

Accepted for publication August 25, 2003.

This study was supported in part by grant RW72M-07427A from the Committee on Research, Academic Sen-

ate, University of California, San Diego, School of Medicine and grant MO1-RR00827 from the General Clinical Research Centers Program of the National Center for Research Resources, National Institutes of Health, Bethesda, Md (Mr Shragg).

We thank Paul Shragg, MA, from the University of California, San Diego, for assistance in data analysis; Patricia East, PhD, in the Division of Adolescent Medicine at the University of California, San Diego, for assistance with data analysis and manuscript review; and Kathleen Chang, BA, for data entry and data analysis.

This study was presented in part at the San Diego Conference on Responding to Child Maltreatment; February 4, 2003; San Diego, and the Pediatric Academic Societies meeting; May 4, 2003; San Francisco, Calif.

Corresponding author and reprints: Joyce A. Adams, MD, University of California San Diego Medical Center, 200 W Arbor Dr, San Diego, CA 92103-8449 (e-mail: jadams@ucsd.edu).

## REFERENCES

1. American Academy of Pediatrics. *Adolescent Health Update*. Vol 1, No 2. Elk Grove Village, Ill: American Academy of Pediatrics; 1989.
2. Edgardh K, Ormstad K. The adolescent hymen. *J Reprod Med*. 2002;47:710-714.
3. Berenson A, Heger A, Andrews S. Appearance of the hymen in newborns. *Pediatrics*. 1991;87:458-465.
4. McCann J, Wells R, Simon M, Voris J. Genital findings in prepubertal girls selected for nonabuse: a descriptive study. *Pediatrics*. 1990;86:428-439.
5. Berenson AB, Heger AH, Hayes JM, Bailey RK, Emans SJ. Appearance of the hymen in prepubertal girls. *Pediatrics*. 1992;89:387-394.
6. Emans SJ, Woods ER, Allred EN, Grace E. Hymenal findings in adolescent women: impact of tampon use and consensual sexual activity. *J Pediatr*. 1994;125:153-160.
7. Adams JA, Harper K, Wells R. How do pediatricians interpret genital findings in children? results of a survey. *Adolesc Pediatr Gynecol*. 1993;6:203-208.
8. Berenson AB, Chacko MR, Wiemann CM, et al. A case-control study of anatomic changes resulting from sexual abuse. *Am J Obstet Gynecol*. 2000;182:820-834.
9. Adams J, East P. Past physical abuse is significantly correlated with pregnancy as an adolescent. *J Pediatr Adolesc Gynecol*. 1999;12:133-138.
10. Cohen J. *Statistical Power for the Behavioral Sciences*. New York, NY: Academic Press; 1977.
11. Starling SP, Jenny C. Forensic examination of adolescent female genitalia: the Foley catheter technique. *Arch Pediatr Adolesc Med*. 1997;151:102-103.